

Clinical Quiz

Fabmi Y. Khan, MD.
Senior Specialist, Department of Medicine,
Hamad General Hospital, PO Box 3050, Doha, Qatar.
Tel. +974 4879228. Fax. +974 4392273. E-mail: fakhanqal@yahoo.co.uk

Notice: Authors are encouraged to submit quizzes for possible publication in the Journal. These may be in any specialty, and should approximately follow the format used here (maximum of 2 figures). Please address any submissions to: Editor, Saudi Medical Journal, Armed Forces Hospital, PO Box 7897, Riyadh 11159, Kingdom of Saudi Arabia. Tel. +966 (1) 4777714 Ext. 6570. Fax. +966 (1) 4761810 or 4777194.

A 36-year-old man with palpitation

Clinical Presentation

A 36-year-old man presented to the emergency department with palpitation associated with dizziness. Electrocardiogram was carried out (Figure 1).

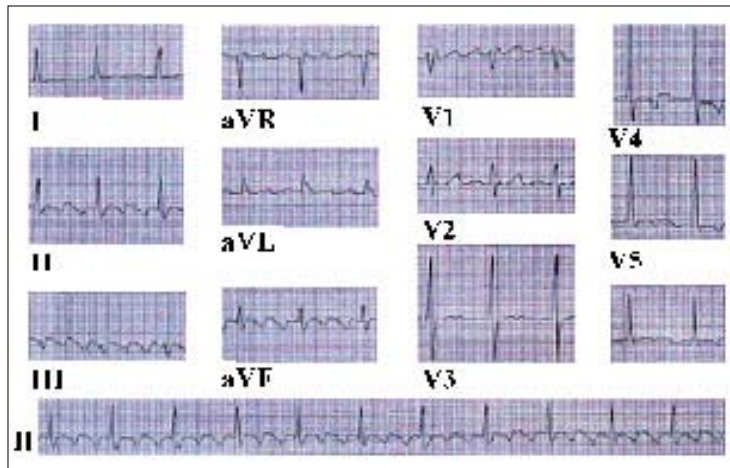


Figure 1 - Electrocardiogram trace.

Questions

1. Interpret the ECG trace.
2. What is the likely diagnosis?
3. Mention the causes of this condition.

Clinical Quiz

Answers

1. The rhythm is irregular. Notice the distinct saw-toothed pattern of these flutter waves. The atrial rate is between 250 and 300/min. The ventricular rate is irregular and demonstrates a slowed ventricular response. The rate fluctuates between 65 and 75 beats per minute. The conduction ratio is 3:1.
2. Atrial flutter.
3. Causes of atrial flutter include: mitral valve disease (rheumatic), primary myocardial disease, coronary artery disease, or pericardial disease. It can occur in thyrotoxicosis, alcoholism, hyperthyroidism or beriberi.

Discussion

Atrial flutter is a rhythm disturbance of the atria that results in regular tachycardic ventricular waveforms. Atrial rates in atrial flutter are generally 240-400 beats per minute. The QRS complexes are uniform in shape but irregular in rate. The P-waves may have saw-toothed configurations.

Electrophysiologic studies indicate that it is caused and maintained by reentrant mechanisms. Multiple reentrant or primarily generated (ectopic) atrial waveforms bombard the atrioventricular (AV) node. The most common form of atrial flutter involves a reentrant circuit that encircles the tricuspid annulus of the right atrium.^{1,2} Atrial flutter can be the result of, mitral valve disease (rheumatic), primary myocardial disease, coronary artery disease, or pericardial disease. It can occur in thyrotoxicosis, alcoholism, hyperthyroidism or beriberi.³⁻⁵

Atrial flutter is subdivided into 2 types.² Typical atrial flutter has a very characteristic electrocardiogram (ECG) pattern and is caused by localized reentry with impulse pathways occupying large portions of the right atrial wall. Since the circuit is fixed and accessible, typical atrial flutter can often be cured by destroying a portion of the circuit during ablation. Atypical atrial flutter, on the other hand, exhibits a more variable ECG pattern, and more than one circuit may be responsible. Atypical atrial flutter behaves much more like atrial fibrillation than does typical atrial flutter.

An episode of atrial flutter can cause heart palpitations, shortness of breath, chest tightness, fatigue and dizziness. Some people may experience no symptoms, and the atrial flutter is identified accidentally during a routine electrocardiogram. Although the condition may be chronic (occurring repeatedly or constantly), it can also occur in episodes where occasional attacks last hours or days, and then followed by periods of normal heart rhythm.

The goals of treatment of atrial flutter are reversion to normal sinus rhythm (NSR), maintenance of NSR, control of the ventricular rate in patients and prevention of systemic embolization, particularly in patient who also has atrial fibrillation.

References

1. Leier, CV, Meacham, JA, Schaal, SF. Prolonged atrial conduction: A major predisposing factor for the development of atrial flutter. *Circulation* 1978; 57: 213.
2. Wells JL Jr, MacLean WA, James TN, Waldo AL. Characterization of atrial flutter. Studies in man after open heart surgery using fixed atrial electrodes. *Circulation* 1979; 60: 665.
3. Friedberg, CK. Diseases of the Heart. Philadelphia (PA): Saunders; 1966.
4. Lewis, T. Diseases of the Heart. London: MacMillan; 1948.
5. Garson A Jr, Bink-Boelkens M, Hesslein PS, Hordof AJ, Keane JF, Neches WH, et al. Atrial flutter in the young: A collaborative study of 380 cases. *J Am Coll Cardiol* 1985; 6: 871.